

Prolotherapy

Platelet Rich Plasma Prolotherapy as First-Line Treatment for Meniscal Pathology

Animal research together with five patient case reports demonstrate that Platelet Rich Plasma Prolotherapy (PRPP) is effective in the treatment of MRI-documented meniscal tears.



Donna Alderman, DO

Meniscus injuries are a common cause of knee pain, accounting for a large number of surgeries in the U.S. annually. While surgical treatments range from total to partial meniscectomy, meniscal repair and even meniscus transplantation, all have a high long-term failure rate with the recurrence of symptoms. The most serious of the long-term post-surgical consequences is an acceleration of joint degeneration. The poor healing potential of meniscus tears, along with the consequence of post-surgical joint degeneration, has led to the investigation of methods to stimulate non-surgical, biological meniscal repair. While platelet rich plasma prolotherapy (PRPP) has been studied for many types of connective tissue injuries, no study has focused specifically on its use for meniscus tears. Hauser et al give a very comprehensive review of the anatomy and pathophysiology of meniscus tears, with five case reports of MRI-documented meniscus tears successfully treated with PRPP. While further study under more controlled circumstances is needed, the logic of the authors' discussion and the results reported clearly validate the use of platelet rich plasma prolotherapy as a first-line treatment for meniscus tears.

— Donna Alderman, DO
Prolotherapy Department Head

By Ross A. Hauser, MD; Hilary J. Phillips; and Havil Maddela

Knee injuries are a common concern resulting in over one million surgeries performed on the knee in the United States every year, including the meniscus.¹⁻³ There are an estimated 650,000 arthroscopic meniscal procedures, with a total number of 850,000 meniscal surgeries performed in the United States every year.¹⁻³ Unfortunately, joint instability is a common result of meniscal procedures, which is not surprising considering that the meniscus is a primary stabilizing component of the knee. One of the principle reasons for meniscal op-

erations is to improve joint stability, yet meniscectomy often appears to have the opposite effect, eliciting even more instability, crepitation, and degeneration than the injury itself produced prior to operation. This is why reoperation rates after meniscectomy can be as high as 29% to improve the joint instability that the meniscectomy caused.⁴⁻⁶ For this reason, it is desirable to look for non-operative interventions whenever possible. Platelet rich plasma prolotherapy offers hope in this direction.

Meniscus Anatomy and Function

There has been a great deal of speculation and research dedicated to what exact function the meniscus serves, but today there is general consensus that the menisci provide stability in the joint, nutrition and lubrication to articular cartilage, and shock absorption during movement.⁷⁻¹¹ The menisci (plural of meniscus) are a pair of C-shaped fibrocartilages which lie between the femur and tibia in each knee, extending peripherally along each medial and lateral aspect of the knee (see Figure 1). The anatomy of both menisci is essentially the same, with the only exception being that the medial meniscus is slightly more circular than its hemispher-

ical lateral counterpart. Each meniscus has a flat underside to match the smooth top of the tibial surface, and a concave superior shape to provide congruency with the convex femoral condyle. Anterior and posterior horns from each meniscus then attach to the tibia to hold them in place.

Stability

Several ligaments work together with the menisci to prevent overextension of any motion. Hypermobility is avoided through ligamentous connections—both medially and laterally. Medially, the medial collateral ligament (MCL) is strongly connected to the medial meniscus, as well as the medial tibial condyle and femoral condyle. Laterally, the lateral collateral ligament (LCL) attaches to the lateral femoral epicondyle and the head of the fibula. These ligaments provide tension and limit motion during full flexion and extension, respectively. The anterior and posterior meniscofemoral ligaments form an attachment between the lateral meniscus and the femur and remain taut during complete flexion. Lastly, the anterior cruciate ligament (ACL) and posterior cruciate ligament (PCL) are responsible for preventing too much backward or forward motion of the tibia.^{9,10}

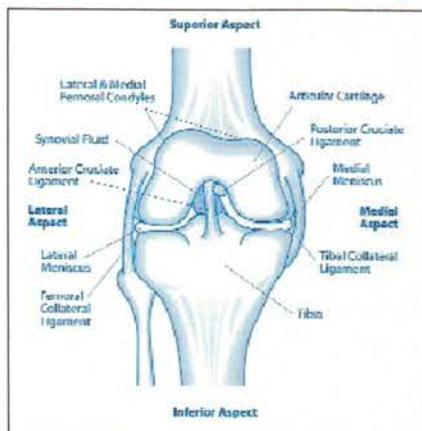


FIGURE 1. Anterior aspect of the right knee.

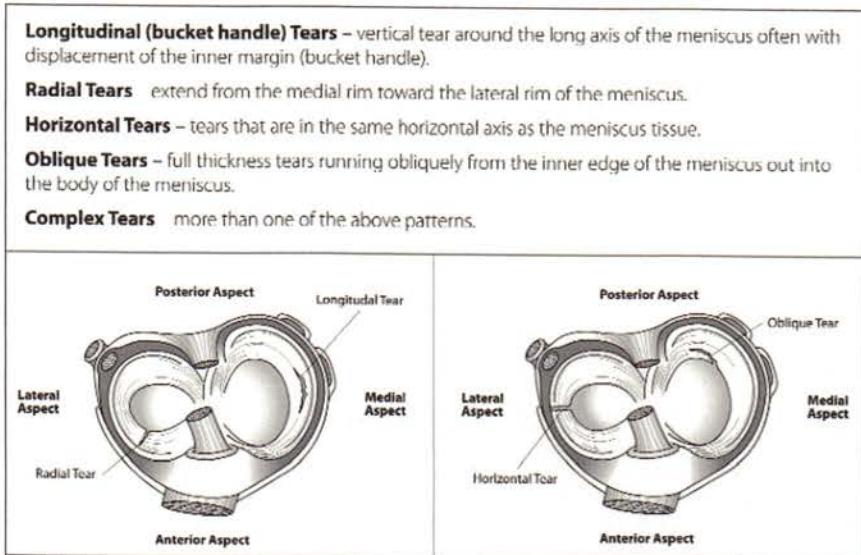


FIGURE 2. Common types of meniscal tears.

Shock Absorption

The menisci also provide shock absorption and stability by equally distributing weight across the joint. By acting as a spacer between the femur and tibia, the meniscus eliminates any direct contact between the bones thus preventing any contact wear.¹² It is estimated that 45% to 70% of the weight-bearing load is transmitted through the menisci in a completely intact joint.⁷ By channeling the majority of this weight evenly, the meniscus is able to avoid placing too much direct stress at any one point of the knee. In turn, proper weight transmission in the knee reduces stress on any other joints in the body affected by load bearing.¹¹

Lubrication and Nutrition

One of the most vital roles of the meniscus is to provide lubrication to the knee, which it accomplishes through diffusing synovial fluid across the joint. Synovial fluid provides nutrition and acts as a protective measure for articular cartilages in the knee.¹³ The femoral condyle in the knee is covered in a thin layer of articular cartilage, which serves to reduce motional friction and to withstand weight bearing. This cartilage is very susceptible to injury—both because of its lack of proximity to blood supply and the high level of stress placed on it by excessive motion.^{14,15} The meniscus, therefore, is able to provide a much-needed source of nutrition to the femoral and tibial articular cartilage by spreading fluid to that avascular area.

Injury

Meniscal damage can be caused by either trauma or gradual degeneration. Traumatic injury is most often a result of a twisting motion in the knee or the motion of rising from a squatting position, both of which place particular strain and pressure on the meniscus. Tears are the most common form of meniscal injury and are generally classified by appearance into four categories: longitudinal tears (also referred to as bucket handle tears), radial tears, horizontal tears, and oblique tears¹⁶ (see Figure 2). Research indicates that radial or horizontal tears are more likely to occur in the elderly population while younger patients have a higher incidence of longitudinal tears.¹⁷⁻¹⁹ Each can be further described as partial thickness tears or complete thickness tears, depending on the vertical depth of the tear (see Figure 3).

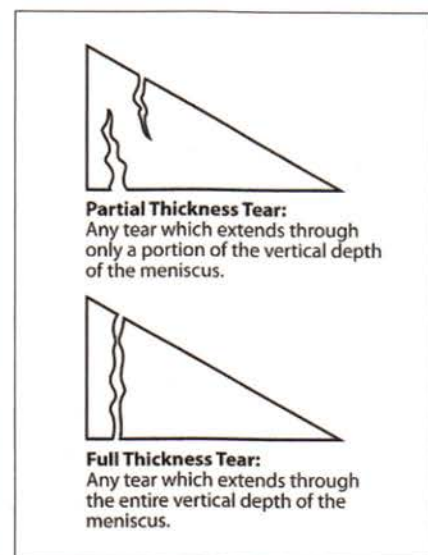


FIGURE 3. Depths of tears in the meniscus.

Limited Blood Supply

An ability to preserve the meniscus, unfortunately, is somewhat hampered by the fact that only a very small percentage (10% to 25% peripherally) of the meniscus receives direct blood supply.²⁰ This area is often referred to as the red zone, and the inner portion of the meniscus which does not receive blood supply is referred to as the white zone (see Figure 4). While the red zone has a moderate chance of healing from injury, the white zone is almost completely incapable of healing itself in the event of injury.²¹

More often than not, traumatic injuries occur during athletic activity (see Figure 5). The ratio of degenerative to traumatic tears increases from equal incidence in those under 20 years of age to a ratio of 7:8 in the 30 to 39 age group and to nearly 4:1 in individuals over the age of 40.²² This pattern of increased degenerative

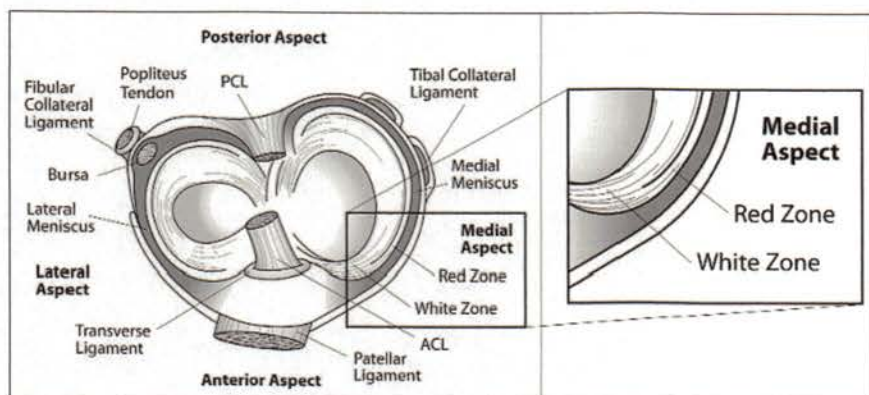


FIGURE 4. Superior aspect of right knee showing red and white zones.

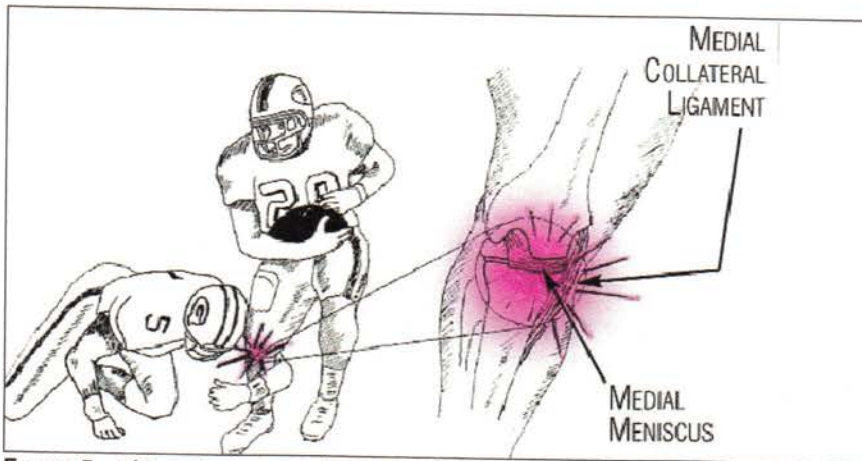


FIGURE 5. A hit on the knee causing a medial collateral ligament injury. If the hit is severe enough, the supporting ligaments of the knee could also be torn. (Used with permission from Hauser, R. *Prolo Your Sports Injuries Away*, Beulah Land Press, Oak Park, Ill. 2001)

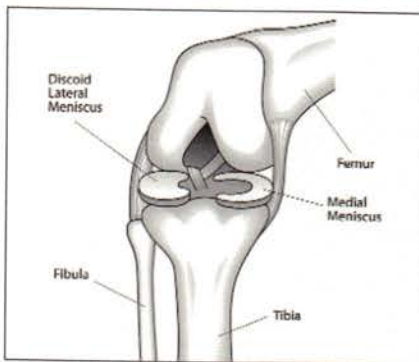


FIGURE 6. Discoid meniscus of right knee.

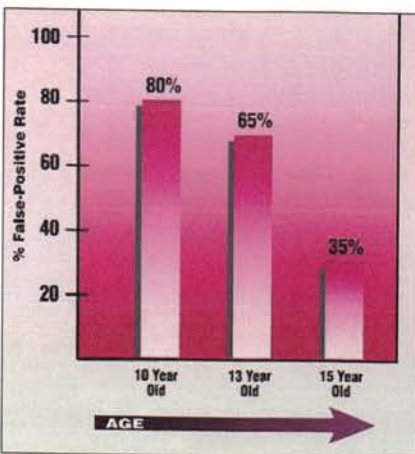


FIGURE 7. False-positive MRIs of the knee in teenagers. Because significant abnormalities show up in the menisci on MRI in teenagers, when no true injury exists, relying on this modality to make a diagnosis is a scary proposition, especially if surgery is contemplated. (Used with permission of Beulah Land Press, 2001, Oak Park, Il. "Prolo Your Sports Injuries Away!" fig. 16-10.)

breakdown is to be expected with age, as joint wear will result from years of mechanical stress. Unlike the anatomy of younger and more active patients, however, the fibers in older patients are less capable of healing themselves due to decreased diffusion of synovial fluid as a result of lessened motion.²³

Symptoms of Meniscal Tears

A basic ability to identify meniscal tear symptoms is essential for diagnosis and treatment of injury (see Table 1). The first symptom typically indicative of a meniscal tear is pain. In the case of a traumatic tear, pain may present immediately at the time of injury and is often accompanied by an audible pop. In a degenerative tear, the onset of pain may be more gradual, with no definite moment of injury. In both cases, pain may be accompanied by swelling and subsequent limitation in range of motion. Another hallmark of meniscal tears is clicking, popping, or locking in the knee joint. These symptoms are mostly likely a result of a torn flap of meniscal tissue which catches in the joint during movement. Instability and weakness are also both common symptoms because a damaged meniscus—as well as damaged ligaments and tendons—inhibits normal mechanical function.

The severity of initiating trauma, as well as the nature and characteristics of the tear, plays an important role in the meniscus' ability to heal (see Table 2). Tears that are shorter, partial thickness, and located in the vascular red zone have a much better chance of healing than extensive, complete thickness tears located in the white

zone.^{24,25} When other cartilages and ligaments are injured in the knee, they can have a detrimental effect on the meniscus' ability to heal on its own. Because of the interdependence of each of the knee's mechanisms, meniscal injuries often occur in conjunction with other internal ligament damage. The most common example of this is O'Donoghue's "unhappy triad," the correlated injury of the meniscus (debatably either medial or lateral), tibial collateral ligament, and ACL.²⁶⁻²⁸ The severity of meniscal lesions has been found to increase in direct proportion to ACL injury and/or laxity and create less favorable conditions for repair.²⁹ Furthermore, previous injury to either the meniscus or any other ligament inside the knee can increase the risk of future injury to the meniscus, even if the injury has healed or been surgically repaired.

Discoid Meniscus Condition

Another condition which can be both a cause and complication of meniscal tears is a discoid meniscus (see Figure 6). A discoid meniscus occurs when the lateral meniscus takes on the shape of a disc rather than a crescent and is most often manifested in adolescence.³⁰ Although the cause has never been officially determined, the repercussions of a discoid meniscus have been widely documented. Often referred to as "snapping knee syndrome," this condition is identified with its only symptom: snapping on extension. The "snap" is caused when the femur and the meniscus are not able to move in sync with each other and the femur either slips over a ridge in the meniscus or off the meniscus altogether.³¹ Unlike the normal meniscus, which is shaped to fit the condyle of the femur, a discoid meniscus lacks the configuration to serve as a stable surface for motion. This abnormal tracking adds stress to the meniscus, increasing the probability of lateral meniscus tears.³² Unfortunately, discoid menisci often remain undetected when no symptoms present prior to injury, and the only other way to identify a discoid meniscus is by magnetic resonance imaging (MRI).

Imaging

For decades, MRI has been used as a primary determinant for meniscal injuries but the fact that it is more sensitive to some tissues than others, however, can prevent it from producing a completely accurate picture of an injured area. This can cause in-

TABLE 1. Symptoms of Meniscus Tears

- Clicking or popping
- Decreased knee range of motion
- Instability
- Joint line tenderness
- Locking
- Pain
- Swelling
- Weakness

jured tissues to remain undetected, or other “abnormalities” on the MRI may be misread as actual injuries (“false-positive”). One study that brought these issues into the spotlight was performed on college basketball players at Duke University who displayed no clinical symptoms of knee abnormality. Internal irregularities of the knee including cartilage defects, joint effusions, bone marrow edema, and even discoid menisci were found on the MRI’s of 75% of subjects, who never displayed any symptoms of meniscal abnormality.³⁵ More distressing is the fact that in another study on children with a mean age 12.2 years, 66% showed a high signal intensity within the menisci.³⁴ A high signal intensity is one of the criterion to diagnose degenerative menisci (see Figure 7).

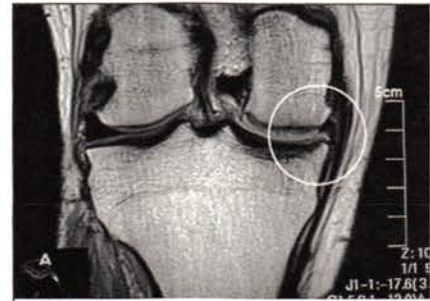Just as MRIs can lead to false-positive readings, they may also produce false-negative findings by failing to detect an actual meniscal injury. This was the case in one study of 254 human knees, where the researchers found patients presenting with normal MRIs, despite exhibiting symptoms of meniscal injury confirmable on arthroscopy.³⁵ Another study published in the *Journal of Arthroscopic Surgery* reported that 35% of their patients would have undergone unnecessary surgery if the examiner had relied on just MRI findings of meniscal tear alone, leading the researchers to conclude that MRIs are “an expensive, unnecessary procedure”³⁵ (see Figure 8). Stanitski found that 71% of his patients were given inaccurate MRI readings, with 24% showing false-positive evidence of meniscal tears, while actual ACL, meniscal, and cartilage injuries went undetected in half of the patients.³⁶ Part of the reason there are so many MRI “abnormalities” in the menisci in asymptomatic individuals is because structures that attach to the menisci can cause an increased signal and produce the false appearance of a meniscal tear.

Perhaps the best study to date to document abnormal meniscal MRI findings in asymptomatic individuals was published in the *New England Journal of Medicine* in 2008.³⁷ In this study MRI scans on 991 knees were taken and compared to patients’ responses about pain and disability in those knees. The MRIs in these patients (aged 50 to 90) showed that over 60% had meniscal tears documented on MRI and that sixty-one percent of subjects who had meniscal tears did not have any pain, aching, or stiffness in their knees.

As seen by these and numerous other studies, MR imaging often disagrees with patients’ clinical symptoms or arthroscopic findings, making it a poor tool for diagnosis. Rushing to surgery based on an MRI alone, therefore, can cause unnecessary surgery resulting in premature degenerative changes and may not solve the pain complaints of the patient.

Limitations of Surgical Repair

Traditional surgical treatments for meniscal injury have been meniscectomy, meniscal repair, and meniscal allograft—each having shortcomings and minimal long-term benefits (see Appendix A). Although there is some short-term improvement in aspects such as pain control, the long term effects of meniscectomy, meniscal repair, and meniscal allograft transplantation reveal that symptoms, such as pain and instability, will persist for years afterward. The main reason that these and other treatments are ineffective in healing the meniscus can simply be attributed to the fact that, regardless of what is done to structurally repair the meniscus, it is still primarily an avascular cartilaginous structure which cannot heal without a sufficient supply of nutrition. The poor healing potential of meniscal tears has led to the in-



Excerpt from Radiologist's MRI Report

Findings: Post surgical changes are demonstrated in medial meniscus with smaller than expected size of body of medial meniscus. Altered signal intensity in body and posterior horn of medial meniscus extending to inferior articular surface demonstrates similar appearance to previous outside MR. This either represents residual changes from prior surgery and meniscal tear or recurrent tear persistent from prior exam.

FIGURE 8. MRI of the right knee without contrast. Noted are changes in the medial meniscus. See how even the radiologist cannot determine whether this represents a recurrent meniscal tear or is just post surgical changes.

vestigation of methods to provide blood supply to the injured area. The methods include vascular access channels and synovial pedicle flaps. Unfortunately, no surgical treatment to date has been shown to stimulate healing of the meniscus. On the contrary, surgeries often have the opposite effect. They initiate additional damage to the joint, further decreasing the probability of healing (see Table 3).

The bottom line is that surgical procedures do not initiate the regenerative process needed in these traumatized knee joints. Left alone or treated by the surgery, the degenerative process initiated by the initial trauma continues, unless something is done to initiate regeneration. The reverse of degeneration is simply regeneration. In other words, a degenerative

TABLE 2. Factors Affecting the Healing of a Torn Meniscus

More Likely to Heal	Less Likely to Heal
<ul style="list-style-type: none"> • Males • Patients <50 years old • Patients with BMI <40 • Traumatic tears • Red zone tears • Radial or oblique tears • Partial thickness tears • Shorter tears • Lateral meniscus • Isolated tears 	<ul style="list-style-type: none"> • Females • Patients 50+ years old • Patients with BMI >40 • Degenerative tears • White zone tears • Horizontal or longitudinal tears • Complete thickness tears • Longer tears • Medial meniscus • Tears with associated injuries

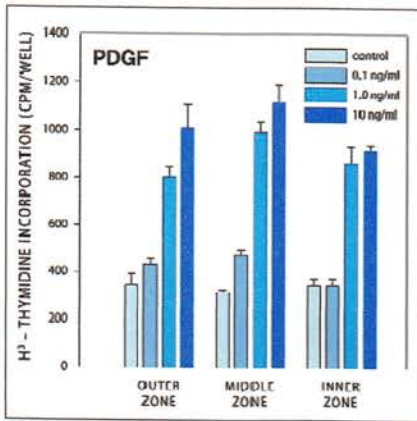


FIGURE 9. Effects of platelet-derived growth factor-AB on DNA synthesis in cells from the three zones of the meniscus. Results are mean + SEM (N=12). Platelet-derived growth factor at 1 and 10ng/ml increased DNA synthesis (in both the middle and inner zones) by over 400% compared with control.⁹⁵

process can only be reversed when stimulated to repair itself. Degeneration of the meniscus is initiated by a damaged meniscus' inability to repair itself, and the surgical procedures themselves accelerate the degenerative process. Therefore, the ideal treatment for a damaged meniscus is one that can stimulate regeneration of the degenerated or torn meniscus.

Platelet Rich Plasma for Meniscal Pathology

In order to understand how growth factors affect the treatment of meniscus injuries, it is first important to understand the role that they play in the natural process of healing. The preliminary steps of healing begin with the attraction of blood cells to the site of an injured tissue. When a tissue is injured, bleeding will naturally occur in that area. A specialized blood component called platelets rapidly migrate into the area to initiate coagulation, or the clotting of blood cells, to prevent excessive bleeding from an injury. In addition, platelets also release growth factors which are an integral part of the healing process. Each platelet is made up of an alpha granule and a dense granule which contain a number of proteins and growth factors. The growth factors contained in the alpha-granule are an especially important component to healing. When activated by an injury, the platelets will change shape and develop branches to spread over injured tissue to help stop the bleeding in a process called aggregation, followed by the release of growth fac-

TABLE 3. Effects of Treatments for Meniscal Tears
Only Prolotherapy stimulates the repair of injured meniscal tissue.

Effects of Treatment	Meniscal removal	Meniscal repair	Meniscal transplant	Untreated injury	Prolotherapy
Articular cartilage deterioration	Yes	Yes	Yes	Yes	No
Bone deformity	Yes	Yes	Yes	Yes	No
Chronic pain	Yes	Yes	Yes	Yes	No
Continuing instability	Yes	Yes	Yes	Yes	No
Joint space narrowing on MRI	Yes	Yes	Yes	Yes	No
Likely to be re-injured	Yes	Yes	Yes	Yes	No
Long term osteoarthritis	Yes	Yes	Yes	Yes	No
Restricted motion	Yes	Yes	Yes	Yes	No
Weakened ligaments	Yes	Yes	Yes	Yes	No
Stimulates meniscus repair	No	No	No	No	Yes

tors, primarily from the alpha granules.

At this point, the healing process then proceeds in three basic stages: inflammatory, fibroblastic, and maturation. After growth factors are released from the platelets, they stimulate the inflammatory stage with each growth factor playing a key role (see Table 4). This stage is marked by the appearance of monocytes which are white blood cells that respond quickly to inflammatory signals and elicit an immune response. Growth factor production is at its highest level immediately following the inflammatory stage. Fibroblasts begin to enter the site within the first 48 hours after an injury and become the most abundant cells in that area by the seventh day. The fibroblasts deposit collagen, the main building block of tissues such as the meniscus, for up to many weeks afterward. The maturation of collagen may then continue for up to one to two years after the initial inflammatory event.

It is important to understand that each of these stages stimulates the next. If the inflammatory stage does not occur, neither will the fibroblastic stage, and so on. If there is not a significant enough immune response to completely regenerate the damaged tissue in any of these stages, the injury will be unable to heal completely, leaving the person with a chronic degenerated knee.

In the case of the injured meniscus, it is clear that the damaged tissue can not repair itself. Healing in the meniscus depends on having enough of a blood sup-

ply and or/growth factors at the site of the injury. Since less than 20% of the meniscus is vascularized by the time a person reaches the age of 40 years, meniscal healing is generally incomplete.⁹¹ Once torn, the menisci, because of its low cellularity and incomplete healing response, is unable to fully repair itself.⁹²

In Vivo and In Vitro Growth Factor Studies to Stimulate Meniscal Repair

Because growth factors are known to be a basic component of healing, the adjunct use of growth factors to stimulate connective tissue repair has been studied as a potential for the treatment of injured soft tissues, including the meniscus. Direct exposure of connective tissues to fibroblastic growth factors can indeed cause new cell growth and formation of collagen. Therefore, injecting growth factors at the site of a soft tissue injury allows the damaged tissue to heal itself.

Before any treatment is tested on humans, it is common practice to investigate the effect of that treatment (in this case growth factors) on cells, as well as on animal models with similar pathology to humans. The primary objective of these studies is to determine if and how a poorly vascularized tissue such as the meniscus can be stimulated for reliable cellular and tissue repair. In such studies, growth factors, such as the ones extracted and secreted from the platelets are incubated with meniscal cells and then injected into injured meniscal tissue to see if cellular

repair and regeneration occurs. Many studies demonstrate that injection of various growth factors can increase meniscal cells activity and stimulate repair in this tissue and other connective tissues.⁹⁵ The ideal mode of treatment for meniscal tears and degeneration would stimulate the production of meniscal fibrochondrocytes and its synthesis of extracellular matrix (ECM). Increased ECM synthesis would render the generated meniscal tissue more able to withstand the forces placed on the knee since it is the collagen, proteoglycans and glycoproteins in the ECM, that give the meniscus its compressive properties to withstand tensile loads.⁹⁴

Platelet-derived growth factor (PDGF) is one growth factor commonly used in animal meniscus studies. One recent study measured both cell proliferation and extracellular collagen matrix formation in each of the inner, middle, and outer regions of sheep menisci in the presence of PDGF-AB. After one week, meniscal cell proliferation was apparent in all three meniscal zones, reaching an 800% increase in the inner vascular zone compared to control. The formation of the collagen matrix had increased by 450% in the middle zone and by 300% in the outer zone (see Figure 9). An increase in the production of glycosaminoglycans, a main component of synovial fluid, in each of the three zones was observed.⁹⁵ Meniscal cell migration was also stimulated.

A similar in vitro study found that cell production of sheep menisci increased in proportion to the increased concentration of PDGF-AB used. This study observed a 2.5-fold increase in cell production.⁹⁶ Another in vitro study placed bovine meniscal cells in different solutions containing cytokines and measured the effect of each on the synthesis of new cells in each of the three meniscal zones. The authors reported that significant DNA synthesis occurred in meniscal cells treated with PDGF-AB, hepatocyte growth factor, and bone morphogenic protein-2 in all three regions.⁹⁷

Similar results were found when analyzing the effect of basic fibroblastic growth factor (bFGF) on meniscal cells from sheep. When cultured in the bFGF, the formation of DNA increased by as much as seven-fold and protein synthesis increased by as much as 15-fold in the inner (avascular) zone of the meniscus. The results of the outer and middle zones likewise yielded statistically significant cell growth.^{98,99} The synthesis of proteoglycans, the prin-

Growth Factor	Action
Platelet-Derived Growth Factor (PDGF)	Attracts immune system cells to the area and stimulates them to proliferate. Has been shown to enhance ligament and tendon healing.
Transforming Growth Factor-β (TGF-β)	Secreted by and affects all major cell types involved in healing. Similar affects as PDGF.
Vascular Endothelial Growth Factor (VEGF)	Helps new blood vessel formation, thereby increasing vascularity in injured areas.
Fibroblast Growth Factor (FGF)	Promotes the growth of the cells involved in collagen and cartilage formation.

ciple component of the extracellular collagen matrix, was specifically measured in another study on sheep menisci. In all meniscal zones, transforming growth factor beta (TGF-β) stimulated proteoglycan production by up to 100% and the proteoglycans were larger than controls. TGF-β also stimulated cell division in the fibrochondrocyte cultures.¹⁰⁰ Other authors have also confirmed that meniscal fibrochondrocytes from all three zones, including the avascular zone, can proliferate and generate new extracellular matrix given the proper stimuli.¹⁰¹⁻¹⁰⁴ Such findings have been the basis of the integration of growth factors in the treatment of meniscal pathology.

One study involved the use of growth factors TGF-β1 and insulin-like growth factor (IGF-1) as an aid in the insertion of meniscal plugs into the avascular portion of the meniscus. This study found that TGF-β1 was effective in forming an attachment between the actual meniscus and the plugs, and IGF-1 was effective in cell proliferation. Both growth factors also significantly increased the cell density of the plugs.¹⁰⁵ Canine menisci with a defect in the avascular portion documented a 10-fold increase in healing by the addition of a fibrin sealant and endothelial cell growth factor.¹⁰⁶ In this study, the ingrowth of new blood vessels (neovascularization) and granulation tissue (connective tissue) to the avascular portion of the meniscus was noted. Growth factors have even been introduced into surgical treatments, particularly meniscal transplantation, to preserve and enhance joint tissue.^{106,107}

The evidence that avascular cells are capable of regeneration when properly stimulated to do so, serves as the basis and rationale for platelet rich plasma prolotherapy in the treatment of meniscal

pathology as described in the following case reports.

Patients and Methods

The five patients were treated at the primary author's private practice, Caring Medical and Rehabilitation Services in Oak Park, Illinois.

The patients received 3.5-4cc of platelet rich plasma Prolotherapy (PRPP) injected inside the joint. Twenty cc's of patient's blood was drawn at the time of treatment. The blood sample, mixed with anticoagulant citrate dextrose solution A (ACD-A), was placed into a centrifuge to separate the platelet rich plasma from the platelet poor plasma. The platelet concentrate system used in this study was Harvest Technologies SmartPREP. Patients were asked to let pain be their guide as far as activity levels after the PRPP.

A premedical student (H.M.) reviewed in-house medical charts of patients who had completed their last prolotherapy treatment at least one year ago and had MRI-documented meniscal tears. H.M. completed phone interviews asking the patients a series of questions with an emphasis on the effect prolotherapy had on their knee pain, stiffness, and return to sports.

Case Report #1

A 21-year-old runner athlete sustained a medial meniscal tear during wrestling. MRI revealed an oblique tear of the posterior horn of the medial meniscus. Because the patient failed physiotherapy and other conservative care the orthopedic surgeon recommended a partial meniscectomy. The patient's parents were prolotherapy patients and hoped that prolotherapy would offer a non-surgical option for their son as well.

The patient was complaining of pain

APPENDIX A.

Traditional Surgical Treatments for Meniscal Injury

Traditional treatment for meniscal injury is surgery. The most aggressive surgical treatment is meniscectomy, which involves either complete or partial removal of the meniscus depending on the horizontal extent of the tear. Guided by arthroscopy, the damaged portion of the meniscus is surgically debrided and removed. In either operation, a peripheral rim of the meniscus must be kept to preserve any form of normal function within the knee. The decision as to whether to remove all or part of the meniscus is based on the severity of the tear, the restriction of activity caused by the tear, and the age of the tear. Total meniscectomy is generally performed on the most severe and avascular tears which cannot be otherwise repaired.^{38,39}

Current surgical techniques for meniscal injuries accelerate menisci and joint degeneration. Perhaps Lohmander et al, in their comprehensive review of surgical procedures for meniscal pathology, said it best: "there is a lack of evidence to support a protective role of repair or reconstructive surgery of the anterior cruciate ligament or meniscus against osteoarthritis development...Osteoarthritis developing in the injured joints is caused by intra-articular pathogenic processes initiated at the time of injury, combined with long-term changes in dynamic joint loading."⁴⁰

To see what effect the absence of the meniscus has on degeneration within the knee, researchers from the UK, at the Institute of Medical and Biological Engineering, conducted an *in vitro* study by mounting dissected bovine knee joints in a pendulum friction simulator and monitoring wear on knee cartilage both with and without a meniscus. Their results showed no change in surface integrity or loss of cartilage with an intact meniscus, but removal of the meniscus resulted in immediate surface wear and cartilage deterioration.⁴¹ A similar study found that 10 years after undergoing meniscectomy, 65% of patients had radiographic evidence of joint space narrowing greater than 50%.⁴²

The results of total meniscectomy have led to a more cautious approach to meniscal excision, particularly with surgical techniques removing only the damaged portion of the meniscus.⁴³⁻⁴⁶ The thought is that if a portion of the meniscus is preserved, then meniscal function will be more normal as well. Studies have confirmed that removing only the torn portion of a meniscus lowers the severity of postoperative complications, shortens the length of hospital recovery and therapy, and reduces overall pain levels—but the nature of postoperative complications remains the same. These risks include degenerative osteoarthritis, joint instability, femoral and tibial surface damage, and risk of re-injury requiring re-operation.^{45,46} Partial meniscectomy, like total meniscectomy, was found—via MRI volume measurement—to cause cartilage loss at a rate of 4.1% per year; a rate that is 78% faster than controls.⁴⁷ Other researchers noted that when meniscal integrity is compromised, such as with partial meniscectomy, the likelihood of developing degenerative arthritis is much increased.^{48,49} One of the main reasons for this is that partial meniscectomy, by definition, puts additional strains on the ligamentous support of the knee to provide stability. Follow-up studies show that ligament laxity in the medial and lateral collateral ligaments and anterior cruciate ligaments is increased with meniscectomies.⁵⁰⁻⁵³ In his study of post sur-

gical function, McGinity et al documented that athletes who have undergone partial meniscectomy and total meniscectomy were equally likely to give up sports altogether as a direct result of the operation.⁵⁴

ADDITIONAL CONSEQUENCES OF SURGERY

Meniscectomy can provide temporary pain relief in the early stages following the operation, especially when an acute tear had caused excessive pain or popping preoperatively. Another immediate result may be a greater feeling of stability if the tear had previously been a source of instability. On long-term follow-up, however, these initial improvements have rarely been shown to last.^{4,39,55} Complete pain relief from meniscectomy is nearly unheard of after more than 10 years and, at that point, more complex issues including limited range of motion, radiographic degeneration, crepitation, and severe functional impairment have usually begun to surface. In many cases, a simple meniscus tear, if operated on, can become a career-ending injury.^{4,5,39,55} In long-term follow-up studies, four to 14 years after a meniscectomy, nearly 50% of patients had to decrease or stop their typical sporting activities.^{39,55} This included adolescents who underwent total meniscectomy. The X-ray progression of the degenerative change paralleled the reduction in activity. Some 17 years after follow-up after total meniscectomy, the incidence of degenerative arthritis as documented by X-ray was 300% more likely in the knee that had the meniscectomy versus the non-operated knee.⁵⁵

This is logical when considering knee anatomy. A knee joint becomes unstable when ligaments, cartilages, or bone structures are weakened and unable to carry out the level of function of a healthy knee. Such is the case when the meniscus is removed from the knee and unable to perform the usual weight-bearing and tracking functions, placing additional stress on the rest of the knee.^{42,56} Common physical symptoms of instability after meniscectomy are crepitation, such as cracking or popping, and locking in the joint. One study following over 1,000 meniscectomy patients found that 10 to 20 years after the surgery, 27% had more crepitus in the knees having undergone meniscectomy than they had in the untreated knees.⁵ In this same group of patients, degenerative changes ranging from flattened tibial and femoral bone surfaces to significant joint space narrowing were found in 62.5% of the patients with X-ray evaluation of their knees.⁴

The greatest risk of partial and total meniscectomy is in the development of long term degenerative osteoarthritis. Numerous studies have confirmed that a large percentage of the meniscectomy population experience joint osteoarthritis later in life.⁵⁷⁻⁶³ One study found that 15 to 22 years after having a meniscectomy, the odds ratio of knee degenerative arthritis was 2.6 after medial meniscectomy and 5.3 after lateral meniscectomy, using the non-operated knee as the control.⁵⁸ In one study, 20 to 29 years after meniscectomy, X-rays showed 53% had significant progression of degenerative arthritis compared to 13% of the non-operated knees.⁵⁹ Another group of researchers found that 21 years after meniscectomy, 71% of operated knees showed signs of at least mild degeneration and 48% showed signs of

moderate or severe joint degeneration.⁶¹ Another study found that 40% of meniscectomies resulted in degenerative osteoarthritis, and many were accompanied by other injuries, including a large number of ligament tears.⁷⁵ One study noted that "although risk factors for post-traumatic osteoarthritis are multifactorial, the primary risk factor that stood out in this study was if a meniscectomy had been performed." In this study the risk of developing osteoarthritis in the knee after meniscectomy was 100%.⁶³

Biomechanically, the development of osteoarthritis can be explained, in part, by the increased stress placed on the tibia and femur post meniscectomy. It is a fact that reducing the size of contact area on a surface increases pressure in the remaining area. Therefore, by removing all or part of the meniscus from the knee, the area through which weight is transmitted in the joint is reduced, thus increasing the pressure on both the tibia and the femur, and their articular cartilage. The amount of contact stress on the tibiofemoral joint can increase by 65% with only a 10% reduction in contact area, and this percentage increases in proportion to the amount of meniscus removed. Complete removal of the meniscus can increase contact stress by as much as 700%⁶¹⁻⁶⁴ (see Figure A1). What this means for any knee without a meniscus is that it now bears the pressure proportional to carrying seven extra people on one knee.

An additional aspect contributing to the acceleration of the osteoarthritic process is through structural wear of the articular cartilage (see Figure A2). By depriving the joint of the ability to lubricate the articular cartilage, the motion of the femur against the tibia will begin to break down the cartilage. When these articular cartilage cells, which are metabolically active, degenerate faster than they can regenerate, the result is the accelerated breakdown (degeneration) within the joint.⁶³ One study, which followed rabbits in three-month intervals after varying levels of injury, found that the amount of cartilage damage sustained was greatest in the meniscectomy subjects, proving this treatment to be even more damaging than non-treatment.⁶⁴ Although osteoarthritis (OA) may have a reputation as a slowly-

developing disease only prevalent in the elderly, this is clearly not the case. Cartilage loss can develop from adolescent injuries and appear as early as a few years after a meniscectomy.⁶⁵⁻⁶⁸ Precursors to OA, such as evidence of biological cartilage alterations, can appear in as little as three months post meniscectomy.^{69,70} Because OA develops steadily with time, this can have devastating effects just five to 10 years after the procedure. The articular cartilage in a knee deteriorates at an average rate of 4.1% per year after meniscectomy.⁷¹ This rate is about twice the rate of normal cartilage loss with aging. After OA forms, the articular cartilage continues to deteriorate in the knee joint at a rate of about four to five percent per year.^{44,45}

MENISCAL REPAIR

As the importance of maintaining complete intact menisci has become more widely recognized, the desire for a less invasive and more curative treatment has been sought out for meniscal injuries. For this reason, many have turned to meniscal repair as their treatment of choice. Meniscal repair utilizes one of several suturing techniques to reattach a torn flap of the meniscus, rather than removing it. In preparation for meniscal repair, the meniscus is generally debrided to remove any tissue that is rendered too loose or "contaminated" to heal, and then the procedure is performed either open or through incision under arthroscopy.⁷² Meniscal repair is generally reserved for peripheral tears that extend into the red zone, because the likelihood of healing is greater in that region.^{72,73}

The short-term results of meniscal repair have varied significantly, with a range of both promising and disappointing outcomes.^{74,75} Another concern associated with meniscal repair is, not surprisingly, long-term degenerative osteoarthritis.⁷⁶⁻⁷⁹ And as the ability to track long-term results has become possible, repair failures and associated symptoms have been observed in large numbers, proving that the effectiveness of this treatment is questionable at best. Preoperative symptoms have been shown to reoccur as early as six months following meniscal re-

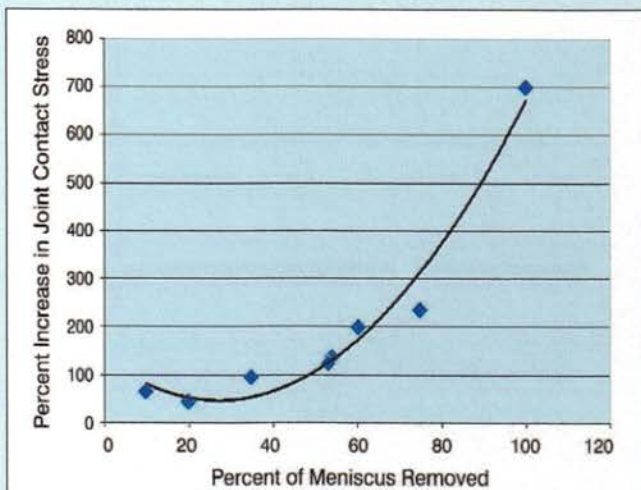


FIGURE A1. Increase in joint contact stress versus percent of meniscus removed. As the percentage of meniscus removed during surgery increases, joint contact stress increases exponentially. Thus arthroscopic meniscectomy dramatically increases the incidence of future degenerative knee arthritis.^{66,67}

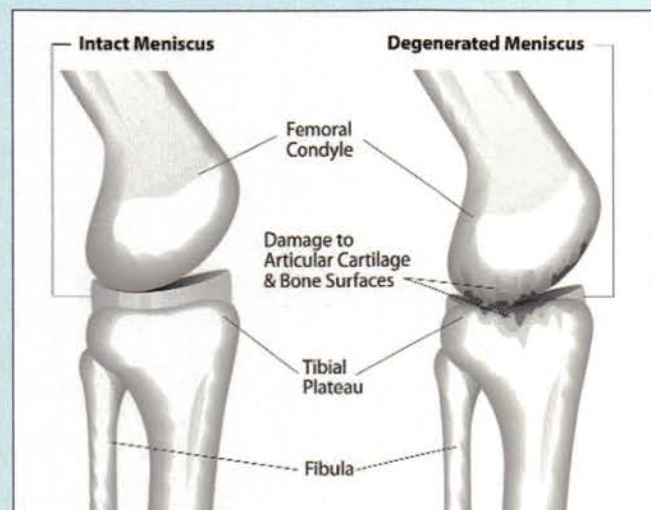


FIGURE A2. Healthy knee joint with intact meniscus and degenerated knee joint without meniscus. The removal of part or all of the meniscus during arthroscopic surgery accelerates the degeneration of the articular cartilage.

pair and can lead to long-term joint damage decades later.^{80,81} Specifically, as documented by CT arthrogram, completely healing from meniscal repair was found in only 58% of the menisci.⁸⁰ After a 13 year follow-up the failure rate in one Swedish study was 29%.⁸¹ In this same study, knee function showed a statistically significant decline in the meniscal-repaired knee compared to the non-operated knee. The authors noted, "We conclude that 13 years after repair, knee function is good but not better than after meniscectomy and not as good as in an uninjured knee." Six independently performed studies, conducted an average of eight years after a repair, found that 10% to 38% of all meniscal repairs were considered failures.⁸²⁻⁸⁷ And in 25% of all patients undergoing meniscal repair, the surgery will either not relieve their symptoms or the repair will fail and their symptoms will again return and need another operation or some other form of therapy.⁷⁸

MENISCAL ALLOGRAFT

The most recent contribution to surgical treatment of meniscus injuries has been the advent of the meniscal transplant. Transplantation can be performed either with human allograft or artificial collagen implants, with the majority utilizing cryopreserved (deep-frozen) allografts extracted from human cadaver knees. Before a transplant can be conducted, the patient must undergo arthroscopic removal of any remaining meniscal tissue to prepare for the new implant. Using one of two techniques—a bone plug or a bridge—the implant is placed inside the knee in alignment with the femur and tibia, and then sutured into place. This procedure requires careful measurement of the meniscus and precision in matching the size and placement of a new meniscus, as even the slightest error in measurement could cause improper tracking and damage to the knee.⁸⁸

This method has been monitored closely for short-term results but, because it is a relatively new treatment and methods between studies have varied, long-term results are difficult to assess. Based on what information we do have, however, the hope of long-term relief remains questionable. In a number of studies spanning from two to seven years after allograft transplantation, failure rates ranged from 28% to 58%, where symptoms such as allograft deterioration, new tears, and unresolved pain symptoms resulted in premature removal of allografts or additional arthroscopic surgeries.⁸⁸⁻⁹⁰ As one study states, "[patients] should be advised that the procedure is not curative in the long term, and additional surgery will most likely be required"⁸⁸ (see Figure A2). Recovery time is another important issue in assessing any treatment, and transplants have a longer rehabilitation time than other meniscal operations. In documented transplantation cases, patients did not begin physical rehabilitation until eight weeks post operation, at which time they were started on non-strenuous activities such as cycling and followed, between nine and 12 weeks post operation, by swimming and walking. Even in the most successful knees, patients were informed that they should never return to arduous physical activity, including athletics.⁸⁹ Meniscal transplantation, having such a high failure rate, diminishes the hope that anyone, especially athletes, would have for maintaining an active lifestyle.

with all activities except walking. He had popping in the knee and locking when trying to go from flexion to extension. Physical examination revealed medial joint laxity as well as a positive anterior drawer sign.

The patient received one session of 3.5cc of platelet rich plasma prolotherapy to the inside of the knee. The anterior cruciate ligament and medial collateral ligament were treated with Hackett-Hemwall prolotherapy using a 15% dextrose, 10% Sarapin® and 0.2% procaine solution as previously described.

Prior to prolotherapy the patient reported pain and stiffness levels of 5 (on a scale of 0 to 10) which decreased to 0 and 1, respectively. Prior to prolotherapy, he was completely incapacitated related to sports and after prolotherapy he was back to running and exercising longer than 60 minutes. When he was questioned 15 months after the PRP prolotherapy session, he said prolotherapy had met his expectations.

Case Report #2

A 39-year-old squash player sustained a right knee injury while playing squash about one year prior to the visit. An MRI revealed a horizontal flap tear in the body of the lateral meniscus and the patient had a trial of physiotherapy without success. The patient did not want to get an arthroscopy which was suggested but instead sought out prolotherapy after an internet search.

The patient complained of pain when running and was unable to play sports. He had crepitation in the knee but no locking. He complained of a deep ache within the knee. Physical examination revealed slight medial ligament laxity but no heat or swelling.

He received two sessions of PRP prolotherapy to his knee, each with 3.5 cc of solution. He also received Hackett-Hemwall prolotherapy to his medial collateral ligament. The patient stated his pain and stiffness levels went from a 6 to a 1 after the prolotherapy. He reported that prior to prolotherapy he was completely incapacitated from running or playing squash but now, 17 months after his PRP prolotherapy treatment, has no limitations.

Case Report #3

A 50-year-old chiropractor sustained medial and lateral meniscal tears after falling in a bicycling accident two years prior. He had tried previous conservative therapy without success in relieving his severe left knee pain. He was completely disabled as far as his previous activities of running and cycling. He did not want to get arthroscopy because of a poor response to an arthroscopy on his right knee several years before.

Beside pain with any type of activity other than walking, he had popping and crepitation in the knee but no locking. He had pain deep within the knee as well as both laterally and medially. He had some generalized laxity of his knee throughout on physical examination.

He received a total of four sessions of PRP prolotherapy to his knee over a one year period of time. His general laxity was also treated with Hackett-Hemwall prolotherapy. The primary reason for such a long time span is that each treatment gave him so much improvement he thought it was his last as he increased his physical activity, only to have some of the pain return. He was contacted twenty-four months after his last PRP prolotherapy session.

Before the prolotherapy he had a pain and stiffness level of 8 and 7 respectively, both of which decreased to a 1 after prolotherapy. He was unable to exercise before prolotherapy but after the PRP prolotherapy he is able to engage in unlimited cycling and is able to run, but has chosen not to run because of his right knee (the one that had arthroscopy). He also said that PRP prolotherapy met his expectations.

Case Report #4

A 52-year-old athlete presented after sustaining an MRI-documented horizontal tear of the posterior horn of the lateral meniscus and oblique tear involving the postern horn of the medial meniscus after falling during running. He had a past history of partial lateral meniscectomy 20 years prior. His symptoms included diffuse knee pain and a feeling of his knee giving way. He also had occasional locking of the knee.

On physical examination, he was found to have medial joint laxity as well as significant crepitation especially on the medial aspect of the knee. He received a single PRP prolotherapy treatment to his knee. At that time he also received Hackett-Hemwall prolotherapy for his medial knee instability. His pain level before prolotherapy was a 7 and stiffness also a 7 but, fourteen months post PRP treatment, his pain level is 0 and stiffness is 1. He was unable to exercise at all before prolotherapy but after treatment he can cycle for two hours and has no limitations with most weight lifting, all swimming and all cycling. He cannot run currently because of an Achilles injury that he is thinking about getting treated with prolotherapy.

Case Report #5

A 46-year-old male with a history of three right knee surgeries and two on the left—including partial meniscectomies on both knees—presented for a prolotherapy evaluation because of presumed recurrent meniscal tears on both knees. The patient's main sport is soccer, but had a recent skiing injury causing bilateral knee swelling and pain for one month prior to the first visit. The patient saw an orthopedist who ordered an MRI which showed the medial meniscal tears.

The patient was adamant about not wanting another knee surgery. He was on nonsteroidal anti-inflammatory medication, which was stopped once PRPP was begun. The complaints in both knees (the right was worse than the left) were swelling, popping and snapping and inability to run at all without significant pain. He felt both knees were unstable. The patient was completely disabled in regard to sports because of the injuries.

On physical examination, there was some slight knee swelling bilaterally as well as evidence of medial knee joint instability bilaterally. Both knees started out with a pain level of 7 and stiffness level of 6, but the patient felt the right knee was significantly more unstable. Both knees were treated intraarticularly with platelet rich plasma prolotherapy, as well as with Hackett-Hemwall prolotherapy on the medial knee for the instability. His right knee required five PRPP treatments and his left four treatments total.

Upon follow-up fifteen months after his last prolotherapy treatment, he stated his right knee pain was still a 0 while stiffness was at 1. His left knee pain and stiffness was at a 0. He stated that over the past year he has been playing soccer without any limitations.

Summary

Meniscus injuries are a common cause of knee pain. Tears are the most common form of meniscal injuries, and have a poor healing ability primarily because less than 25% of the menisci receive a direct blood supply. While surgical treatments have ranged from total to partial meniscectomy, one of the most serious long-term sequelae of surgeries for meniscus tears is an acceleration of joint degeneration. This poor healing potential of meniscal tears has led to the investigation of methods to stimulate biological meniscal repair. Research has shown that damaged menisci lack the growth factors to heal. In vitro studies have found that growth factors, including platelet-derived growth factor (PDGF), transforming growth factor (TGF), and others augment menisci cell proliferation and collagen growth manifold. Animal studies with these same growth factors have confirmed that meniscal tears can be stimulated to repair with various growth factors or solutions that stimulate growth factor production. Platelet rich plasma prolotherapy has been shown to be effective in these five cases of MRI-documented meniscal tears in returning these patients to activity and athletic sports. While more controlled studies need to be completed, the clinical evidence shows that PRPP is a reasonable approach to meniscal injury and should be considered as first-line treatment for meniscal injuries. ■



Ross A. Hauser, MD received his undergraduate degree from University of Illinois. He graduated from the University of Illinois College of Medicine in Chicago and did his residency at Loyola/Hines VA in Physical Medicine and Rehabilitation. He is the Medical Director of Caring Medical and Rehabilitation Services in Oak Park, Illinois and is passionate about prolotherapy and natural medicine. He and his wife Marion, have written seven books on prolotherapy, including the national best seller "Prolo Your Pain Away! Curing Chronic Pain with Prolotherapy," now in its third edition, a four-book mini series of Prolotherapy books, and a 900-page epic sports book on the use of prolotherapy for sports injuries. Dr. Hauser may be reached at 715 Lake St., Suite 600, Oak Park, IL 60301; 708-848-7789; www.caringmedical.com.

Hilary J. Phillips received her Associate of Science degree from Triton College, in River Grove, Illinois. Her previous medical experience includes volunteering at Beulah Land Natural Medicine Clinic and working as medical assistant in skilled care geriatric nursing. She also served as a medical assistant for over a year at Caring Medical and Rehabilitation Services. Hilary is currently a student at North Park University where she is pursuing a Bachelor of Science degree in chemistry.



Havil S. Maddela currently works as a medical assistant at Caring Medical and Rehabilitation Services in Oak Park, Illinois. He is currently enrolled in the pre-med program at Loyola University, Chicago where he graduated in May 2010 with a degree in biology. He worked in a medical missionary clinic during his high school years as well. He hopes to attend Medical School in the fall of 2010. He may be reached at 715 Lake St., Suite 600, Oak Park, IL 60301; 708-848-7789; www.caringmedical.com.

715 Lake St., Suite 600, Oak Park, IL 60301; 708-848-7789; www.caringmedical.com.

References

1. Baker BE et al. Review of meniscal injury and associated sports. *Am J Sports Med.* 1985. 13(1): 1-4.
2. DeFrances CJ et al. 2006 National Hospital Discharge Survey. National Center for Health Statistics. National Health Statistics Reports, No. 5. 2008.
3. Owings MF et al. Ambulatory and inpatient procedures in the United States, 1996. Vital and health statistics. Series 13. No 139. Hyattsville, Md.: National Center for Health Statistics. November 1998. (DHHS publication no (PHS) 99-1710.)
4. Hoser C et al. Long-term results of arthroscopic partial lateral meniscectomy in knees without associated damage. *J Bone Joint Surg Br.* 2001. 83-B(4): 513-516.
5. Tapper EM et al. Late results after meniscectomy. *J Bone Joint Surg Am.* 1969. 51-A(3): 517-603.
6. Sharma L et al. Relationship of meniscal damage, meniscal extrusion, malalignment, and joint laxity to subsequent cartilage loss in osteoarthritic knees. *Arthritis & Rheumatism.* 2008. 58(6): 1716-1726.
7. Brindle T et al. The meniscus: review of basic principles with application to surgery and rehabilitation. *Journal of Athletic Training.* 2001. 36(2): 160-169.
8. King D. The function of semilunar cartilages. *J Bone Joint Surg Am.* 1936. 18(4): 1069-1076.
9. Brantigan OC et al. The mechanics of the ligaments and menisci of the knee joint. *J Bone Joint Surg Am.* 1941. 23:44-66.
10. Last RJ. Some anatomical details of the knee joint. *J Bone Joint Surg.* 1948. 30(4): 683-688
11. Bourne RB et al. The effect of medial meniscectomy on strain distribution in the proximal part of the tibia. *J Bone Joint Surg Am.* 1984. 66-A(9): 1431-1437.
12. Messner K et al. The menisci of the knee joint: anatomical and functional characteristics, and a rationale for clinical treatment. *J Anat.* 1998. 193:161-178.
13. Davies DV et al. The blood supply of the synovial membrane and intra-articular structures. *Ann R Coll Surg Engl.* 1948. 2(3): 142-156.
14. Trias A. Effect of persistent pressure on articular cartilage: an experimental study. *J Bone Joint Surg.* 1961. 43-B(2): 376-386.
15. Mankin HJ. The response of articular cartilage to mechanical injury. *J Bone Joint Surg.* 1982. 64-A(3): 460-466.
16. Greis PE et al. Meniscal injury I: basic science and evaluation. *J Am Acad Orthop Surg.* 2002. 10(3): 168-176.
17. Shakespeare DT et al. The bucket-handle tear of the meniscus: a clinical and arthrographic study. *J Bone Joint Surg Br.* 1983. 65-B(4): 383-387.
18. Andrish H. Meniscal injuries in children and adolescents: diagnosis and management. *J Am Acad Orthop Surg.* 1996. 4(5): 231-237.
19. Englund M et al. Incidental meniscal findings on knee MRI in middle-aged and elderly persons. *N Engl J Med.* 2008. 359(11): 1108-1115.
20. Arnoczky SP et al. Microvasculature of the human meniscus. *Am J Sports Med.* 1982. 10(2): 90-95.
21. King D. The healing of semilunar cartilages. *J Bone Joint Surg Am.* 1936. 18(2):333-342.
22. Drosos GI et al. The causes and mechanism of meniscal injuries in the sporting and non-sporting environment in an unselected population. *The Knee.* 2003. 11: 143-149.
23. Petersen W et al. Age-related blood and lymph supply of the knee menisci. *Acta Orthop Scand.* 1995. 66(4): 308-312.
24. Belzer JP et al. Meniscus tears: treatment in the stable and unstable knee. *J Am Acad Orthop Surg.* 1993. 1(1): 41-47.
25. Scott GA et al. Combined posterior incision and arthroscopic intra-articular repair of the meniscus: an examination of factor affecting healing. *J Bone Joint Surg Am.* 1986. 68(6): 847-861.
26. O'Donoghue DH. Surgical treatments of fresh injuries to the major ligaments of the knee. *J Bone Joint Surg Am.* 1950. 32: 721-738.
27. Shelbourne KD et al. The O'Donoghue triad revisited: combined knee injuries involving anterior cruciate and medial collateral ligament tears. *Am J Sports Med.* 1991. 19: 474-477.
28. De Pablos Fernandez J et al. The O'Donoghue terrible triad observations on 34 anterior cruciate ligament (ACL) injuries in adolescents and pre-adolescents. *J Bone Joint Surg Br.* 2006. 88-B: 118.
29. Cipolla M et al. Different patterns of meniscal tears in acute anterior cruciate ligament (ACL) ruptures and in chronic ACL-deficient knees. *Knee Surg, Sports Traumatol, Arthroscopy.* 1995. 3: 130-134.
30. Yaniv M, et al. The discoid meniscus. *J Child Orthop.* 2007. 1(2): 89-96.
31. Smillie IS. The congenital discoid meniscus. *J Bone Joint Surg.* 1948. 30-B(4): 671-682.
32. Rohren EM et al. Discoid lateral meniscus and the frequency of meniscal tears. *Skeletal Radiology.* 2001. 30(6): 316-320.
33. Major NA et al. MR imaging of the knee: findings in asymptomatic collegiate basketball players. *AJR.* 2002. 179:641-644.
34. Takeda Y. MRI high-signal intensity in the menisci of asymptomatic children. *J Bone Joint Surg.* 1998. 80B: 463-467.
35. Quinn SF et al. Meniscal tears diagnosed with MR imaging versus arthroscopy: how reliable a standard is arthroscopy? *Radiology.* 1991. 181(3): 843-847.
36. Stanitski CL. Correlation of arthroscopy and clinical examination with magnetic resonance imaging findings in injured knees in children and adolescents. *Am J Sports Med.* 1998. 26(1): 2-6.
37. Englund M et al. Incidental meniscal findings on knee MRI in middle-aged and elderly persons. *N Engl J Med.* 2008. 359P: 1108-1115.
38. McCarty EC et al. Meniscal tears in the athlete: operative and non-operative management. *Phys Med Rehabil Clin N Am.* 2000. 11(4): 867-880.
39. Jorgensen U et al. Long-term follow-up of meniscectomy in athletes. *J Bone Joint Surg.* 1987. 69-B(1): 80-83.
40. Lohmander LS et al. The long-term consequences of anterior cruciate ligament and meniscal injuries: osteoarthritis. *Am J Sports Med.* 2007. 35: 1756-1769.
41. McCann L et al. *Influence of the meniscus on friction and degradation of cartilage in the knee joint.* Available at: <http://www.ncbi.nlm.nih.gov/pubmed/19328878>. Accessed June 4, 2009.
42. Aglietti P et al. Arthroscopic meniscectomy for discoid lateral meniscus in children and adolescents: a 10-year follow-up. *Am J Knee Surg.* 1999. 12(2):83-87.
43. Hanna F. Factors influencing longitudinal change in knee cartilage volume measured from magnetic resonance imaging in healthy men. *Annals of Rheumatic Diseases.* 2005. 64: 1038-1042.
44. Fairbank TJ. Knee joint changes after meniscectomy. *J Bone Joint Surg.* 1948. 30-B(4): 664-670.
45. Gelber AC et al. Joint injury in young adults and risk for subsequent knee and hip osteoarthritis. *Annals of Internal Medicine.* 2000. 133(5): 321-328.
46. Appleyard RC et al. Biomechanical, histological, and immunohistological studies of patellar cartilage in an ovine model of osteoarthritis induced by later meniscectomy. *Osteoarth & Cartilg.* 1999. 7(3):281-294.
47. Cicuttiini FM et al. Rate of knee cartilage loss after partial meniscectomy. *J Rheumatology.* 2002. 29(9): 1954-1956.
48. Raynauld JP et al. Long term evaluation of disease progression through the quantitative magnetic resonance imaging of symptomatic knee osteoarthritis patients: correlation with clinical symptoms and radiographic changes. *Arthritis Research & Therapy.* 2006. 8(1): R21.
49. Wiuka A et al. Knee cartilage loss in symptomatic knee osteoarthritis over 4.5 years. *Arthritis & Research Therapy.* 2006. 8(4): R90.
50. Johnson RJ et al. Factors affecting late results after meniscectomy. *J Bone Joint Surg.* 1974. 56-A(4): 719-729.
51. Tapper EM et al. Late results after meniscectomy. *J Bone Joint Surg Am.* 1969. 51-A(3): 517-603.
52. Williams RJ et al. MRI evaluation of isolated arthroscopic partial meniscectomy patients at minimum five-year follow up. *Hosp for Spec Surg (HSS) J.* 2007. 3(1): 35-43.
53. Hede A, et al. Partial versus total meniscectomy: a prospective, randomized study with long-term follow-up. *J Bone Joint Surg.* 1992. 74-B(1): 118-121.
54. McGinity JB et al. Partial or total meniscectomy: a comparative analysis. *J Bone Joint Surg Am.* 1977. 59-A(6): 763-766.
55. McNicholas MJ et al. Total meniscectomy in adolescents: a thirty-year follow-up. *J Bone Joint Surg Br.* 2000. 82-B(2): 217-221.
56. Roos E. Joint injury causes knee osteoarthritis in young adults. *Curr Opin Rheumatol.* 2005. 17(2): 195-200.
57. Allen PR et al. Late degenerative changes after meniscectomy: factors affecting the knee after operation. *J Bone Joint Surg.* 1984. 66-B(5): 666-671.
58. Englund M, et al. Patellofemoral osteoarthritis co-existent with tibiofemoral osteoarthritis in a meniscectomy population. *Ann Rheum Dis.* 2005. 64: 1721-1726.
59. Jackson JP. Degenerative changes in the knee after meniscectomy. *Brit Med J.* 1968. 2: 525-527.
60. Rangger C. Osteoarthritis after arthroscopic partial meniscectomy. *Am J Sports Med.* 1995. 23(2): 240-241.
61. Roos H et al. Knee osteoarthritis after meniscectomy: prevalence of radiographic changes after twenty-one years, compared with matched controls. *Arthritis & Rheumatism.* 1998. 41(4): 687-693.
62. Dandy DJ et al. The diagnosis of problems after meniscectomy. *J Bone Joint Surg.* 1975. 57-B(3): 349-352.
63. Neuman P et al. Prevalence of tibiofemoral osteoarthritis 15 years after nonoperative treatment of anterior cruciate ligament injury: a prospective cohort study. *Am J Sports Med.* 2008. 36: 1717-1725.
64. Hoshino A et al. Impact-absorbing properties of the human knee. *J Bone Joint Surg.* 1987. 69-B(5): 807-811.
65. Wilson W et al. Pathways of load-induced cartilage damage causing cartilage degeneration in the knee after meniscectomy. *J Biomechanics.* 2003. 36: 825-851.
66. Baratz MA et al. Meniscal tears: the effect of meniscectomy and of repair on intraarticular contact areas and stress in the human knee: a preliminary report. *Am J Sports Med.* 1986. 14: 270-275.
67. Lee SJ et al. Tibiofemoral contact mechanics after serial medial meniscectomies in the human cadaveric knee. *Am J Sports Med.* 2006. 34(8): 1334-1344.
68. Hunter DJ et al. The association of meniscal pathologic changes with cartilage loss in symptomatic knee osteoarthritis. *Arthritis & Rheumatism.* 2006. 54(3): 795-801.
69. Sandell L, et al. Articular cartilage and changes in arthritis: cell biology of osteoarthritis. *Arthritis Research & Therapy.* 2001. 3(2): 107-113.
70. Hede A et al. Articular cartilage changes following meniscal lesions: repair and meniscectomy studied in rabbit knee. *Acta Orthop Scand.* 1991. 62(4):319-322.
71. Krause WR et al. Mechanical changes in the knee after meniscectomy. *J Bone Joint Surg Am.* 1976. 58-A(5): 599-604.
72. Greis PE et al. Meniscal injury II: management. *J Am Acad Orthop Surg.* 2002. 10(3): 177-187.

73. Cannon WD et al. Meniscal repair: part II: arthroscopic repair techniques. *J Bone Joint Surg Am*. 1994. 76: 294-311.
74. O'Shea JJ et al. Repair of locked bucket-handle meniscal tears in knees with chronic anterior cruciate ligament deficiency. *Am J Sports Med*. 2003. 31(2): 216-219.
75. Bach BR et al. Arthroscopic meniscal repair: analysis of treatment failures. *J Knee Surg*. 2005. 18(4).
76. Abdelkafy A et al. Two to nineteen years follow-up of arthroscopic meniscal repair using the outside-in technique: a retrospective study. *Arch Ortho and Trauma Surg*. 2007. 127(4): 245-252.
77. Hamberg P et al. Suture of new and old peripheral meniscus tears. *J Bone Joint Surg Am*. 1983. 65-A(2): 193-197.
78. Kurosaka M et al. Repeat tears of repaired menisci after arthroscopic confirmation of healing. *J Bone Joint Surg Br*. 2002. 84-B(1): 34-37.
79. Falazare JJ et al. Meniscal repair of the knee. *Orthopaedics*. 2002. 32: 199-206.
80. Pujol N et al. Meniscal healing after meniscus repair: a CT arthrography assessment. *Am J Sports Med*. 2008. 36(8): 1489-1495.
81. Rockborn P et al. Results of open meniscus repair: long-term follow-up study with a matched uninjured control group. *J Bone Joint Surg Br*. 2000. 82-B(4): 494-498.
82. DeHaven KE et al. Open meniscus repair. *Am J Sports Med*. 1989. 17(6): 788-795.
83. DeHaven KE et al. Long-term results of open meniscal repair. *Am J Sports Med*. 1995. 23: 524-530.
84. Eggl S et al. Long-term results of arthroscopic meniscal repair: an analysis of isolated tears. *Am J Sports Med*. 2008. 36: 1489-1495.
85. Morgan CD et al. Arthroscopic meniscal repair evaluated by second-look arthroscopy. *Am J Sports Med*. 1991;19:632-638.
86. Rubman MH, et al. Arthroscopic repair of meniscal tears that extend into the avascular zone: a review of 98 single and complex tears. *Am J Sports Med*. 1998. 26:87-95.
87. Krych AJ et al. Arthroscopic repair of isolated meniscal tears in patients 18 years and younger. *Am J Sports Med*. 2008. 36(7): 1283-1289.
88. Farr J et al. Current meniscal allograft transplantation. *Sports Med Arthroscop Rev*. 2004. 12(1): 69-82.
89. Noyes FR et al. Meniscal transplantation in symptomatic patients less than fifty years old. *J Bone Joint Surg*. 2004. 86-A(7): 1392-1404.
90. Cole B et al. Allograft meniscal transplantation: background techniques and results. *J Bone Joint Surg*. 2002. 84A: 1236-1250.
91. Peters TJ et al. Studies on the chemical composition of the menisci of the knee joint with special reference to the horizontal cleavage lesion. *Clinical Orthopaedics*. 1972. 86: 245-252.
92. Rodkey WG. *Basic biology of the meniscus and response to injury*. Instructional Course Lecture. 2000. 49:189-193.
93. Crane D et al. Platelet rich plasma (PRP) matrix grafts. *Pract Pain Manag*. 2008. 8(1): 12-26.
94. McDevitt CA et al. The ultrastructure and biochemistry of meniscal cartilage. *Clinical Orthopaedics*. Mar 1990. 252: 8-18.
95. Bhargava MM et al. The effect of cytokines on the proliferation and migration of bovine meniscal cells. *Am J Sports Med*. 1999. 27: 636-643.
96. Spindler KP et al. Regional mitogenic response of the meniscus to platelet-derived growth factor (PDGF-AB). *J Orthopaed Research*. 2005. 13: 201-207.
97. Bhargava MM et al. Effect of hepatocyte growth factor and platelet-derived growth factor on the repair of meniscal defects. *In Vitro Cellular & Developmental Biology-Animal*. 2005. 41(8/9): 305-310.
98. Murray MM et al. Enhanced histologic repair in a central wound in the anterior cruciate ligament with a collagen-platelet-rich plasma scaffold. *J Orthopaed Research*. 2007. 25: 1007-1017.
99. Tumia NS et al. Promoting the proliferative and synthetic activity of knee meniscal fibrochondrocytes using basic fibroblast growth factor in vitro. *Am J Sports Med*. 2004. 32: 915-920.
100. Hashimoto J et al. Meniscal repair using fibrin sealant and endothelial growth factor. *Am J Sports Med*. 1992. 20: 537-541.
101. Pangborn CA et al. Growth factors and fibrochondrocytes in scaffolds. *J Orthopaed Research*. 2010. 23: 1184-1190.
102. Pangborn CA et al. Effects of growth factors on meniscal fibrochondrocytes. *Tissue Engineering*. 2005. 11: 1141-1148.
103. Tumia NS et al. Platelet derived growth factor-AB enhances knee meniscal cell activity in vitro. *The Knee*. 2009. 16: 73-76.
104. Webber RJ et al. Cell culture of rabbit meniscal fibrochondrocytes: proliferative and synthetic response to growth factors and ascorbate. *J Orthopaed Research*. 2005. 3: 36-42.
105. Izal I et al. In vitro healing of avascular meniscal injuries with fresh and frozen plugs treated with TGF-BA and IGF-1 in sheep. *Int'l J Experimental Pathology*. 2008. 1: 426-434.
106. Martinek V et al. Second generation of meniscus transplantation: in vivo study with tissue engineered meniscus replacement. *Arch Orthopaed Trauma Surg*. 2006. 126: 228-234.
107. Sclafani AP et al. Modulation of wound response and soft tissue ingrowth in synthetic and allogenic implants with platelet concentrate. *Arch Facial Plast Surg*. 2005. 7: 163-169.